

## Management of Exuberant Granulation Tissues in a Donkey (*Equus africanus asinus*) With Concurrent Trypanosomosis and Oxyuriasis: A Case Report

Rahamon A. M. Adedokun<sup>1</sup>, \*Abayomi K. Olaifa<sup>2</sup>, Bukola A. Alaba<sup>1</sup>, Cecilia O. Oguntoye<sup>2</sup>, Theophilus A. Jarikre<sup>3</sup> and Oghenemega D. Eyarefe<sup>2</sup>

<sup>1</sup>Department of Veterinary Medicine, University of Ibadan, Ibadan, Nigeria

<sup>2</sup>Department of Veterinary Surgery and Radiology, University of Ibadan, Ibadan, Nigeria

<sup>3</sup>Department of Veterinary Pathology, University of Ibadan, Ibadan, Nigeria

\*Corresponding Author's Email: akolaifa@yahoo.com

### ABSTRACT

Wound closure at the distal extremities, in equine species is often impaired by less skin, excessive tension, significant tissue loss and ineffective treatment methods; making it a major challenge to the species' health and functions. This paper reports, a case of a chronic wound with exuberant granulation tissues at the distal extremities of a 4 year-old male donkey that resolved following diagnosis of trypanosomosis and oxyuriasis and management with medical and surgical options. The immunosuppressive effects of trypanosomosis and neuro-pruritic discomfort caused by *Oxyuris equi*, including the slow healing progression of wounds of the distal extremities on the equine species' health and functions are discussed.

**Keywords:** EGT, Wound Healing, hypergranulation, surgical excision, equine species.

### Aims Research Journal Reference Format:

Adedokun, R.A.M., Olaifa, A.K., Alaba, B.A., Oguntoye, C.O., Jarikre, T.A., & Eyarefe, O.D. (2022): Management of Exuberant Granulation Tissues in a Donkey (*Equus africanus asinus*) With Concurrent Trypanosomosis and Oxyuriasis: A Case Report. *Advances in Multidisciplinary and Scientific Research*. Vol. 8. No. 2, Pp 11–20. [www.isteams.net/aimsjournal](http://www.isteams.net/aimsjournal)  
DOI: [dx.doi.org/10.22624/AIMS/V8N2P2](https://doi.org/10.22624/AIMS/V8N2P2)

### 1. INTRODUCTION

The donkey (*Equus africanus asinus*) is a member of the equidae family and has been used as a working animal for at least 5000 years primarily for transportation of farm produce to the market and pulling of carts for farm tillage (Starkey and Starkey, 2004). In Africa, the population of donkeys is growing, and the animal is becoming highly essential for farming activities, transportation of loads at motor pack and recreational riding (Blench, 2004). Wounds are common among equines especially donkeys due to their routine activities and environment (paganela *et al.*, 2009). Equine wound healing rates varies among breeds, wound location and possess a high tendency for excessive granulation tissue production during the healing process (Williams *et al.*, 2018). The equids also have a reputation for developing non-healing wounds, particularly wounds near the joints of the distal limb extremities; due to less skin tissues at this location, and when injury involves a large amount of tissue loss (Ali and Radad 2011; Fiorella *et al.*, 2014).

Foreign objects such as farm tools, construction materials, improper harnessing and infectious diseases are the most prevalent causes of equine limb injuries (Nejash *et al.*, 2017). The formation of granulation tissue is a critical component of wound healing and functions to fill the dead space, and through its rich vascular network and fibroplasia provides early strength and blood flow that aid in infection prevention and wound contraction (Wilmink and Van Weeren 2004). The concomitant exuberant granulation tissue has been associated with longer debridement and repair phase including slower rates of wound contraction and epithelization compared with wounds in other body parts (Ali and Radad 2011; Theoret & Wilmink 2013; Vincenzo *et al.*, 2018). Factors such as body size, wound location and wound care promote exuberant granulation tissue in equids (Wilmink J.M. and Van Weeren P.R. 2004). Management of exuberant granulation tissue depends, to a certain extent, on the chronicity of the wound and the nature of the granulation tissue.

In young, oedematous granulation tissue bulging just above the margin of the wound can be limited by moderate pressure exerted by bandage dressings (Theoret & Wilmink, 2017). Cryogenics, chemical cauterizing agents (silver nitrate, triple dye, potassium permanganate, copper sulfate, dilute hypochlorite, lye, and 4% formaldehyde solution) have been used for treatment of EGT with varying results (Bertone 1989; Vincenzo *et al.*, 2018). These agents are currently contraindicated as they induce necrosis, stimulate chronic inflammation, damage new epithelial border, and ultimately inhibit healing through promotion of granulation tissue proliferation (Theoret & Wilmink, 2017). Surgical excision of the protruding tissue is preferred as it is simple to perform, provides histological assessment of tissue, and maintains the epithelial margin (Bertone 1989; Wilmink and Van Weeren 2004). Prevention of EGT can be done by excluding causal factors, particularly those that are related to inflammation and infection, use of bandages and skin graft.

The fact that bandages favour the formation of EGT, which can subsequently delay healing, must not be taken to mean that healing can be stimulated by omitting bandages and when managed correctly, EGT does not delay healing, and bandages provide more advantages than disadvantages (Theoret & Wilmink 2017). Moreover, the formation of EGT can be limited by selecting an appropriate wound dressing. The objective of this report is to describe the successful handling of an exuberant granulation tissue with concurrent trypanosomiasis and oxyuriasis by medical options and surgical excision respectively.

## **2. CASE REPORT**

### **2.1. Case History**

A 4 year old male Donkey (Biggy), weighing 74kg was presented to University of Ibadan Veterinary Teaching Hospital, Ibadan, Nigeria with history of bilateral swollen masses around the knee joints (Fig 1a and 1b) and around the left elbow joint (Fig 1c). The growths were observed 2 months prior to presentation secondarily from a wound sustained from kicks of a ram during fight.

### **2.2. Clinical Findings**

*Physical examination:* Donkey was dull and inactive, rectal temperature was 38.1°C, capillary refill time was longer than 2 seconds, mucous membrane was pale with no lymphadenopathy. Respiratory rate was 48 breaths per min, Heart rate was 80 beats per min, and pulse rate was 68 beats per min.

No ectoparasites were found on the body. The three nodular mass (5cm x 4cm x 5cm) were very firm, whitish and haemorrhagic. Blood obtained via jugular venipuncture and analysed for Haematology, revealed; severe macrocytic hypochromic anaemia (PCV of 15%), moderate leukocytosis characterized by mild neutrophilia without left shift and moderate parasitaemia with *Trypanosoma congolense*. Serum chemistry report showed mild hyperglobulinaemia. Coprology results also revealed *Oxyuris equi* infestation.

### 2.3. Tissue Exfolatory (Biopsy) examination

Cytological examination of Giemsa stained smear of the fine needle aspirate from the nodule yielded scanty individuals plumb cells with wispy cytoplasmic pattern. Also, there were numerous degenerate neutrophils, and few macrophages some of which contained a few bacteria cocci.

### 2.4. Treatment

Following clinical and laboratory findings, the donkey was treated with 259mg (7.4ml) double diluted Diminazene aceturate (3.5mg/kg) intramuscularly once; 166.5 mg of Vitamin B- complex (thiamine hydrochloride BP 10mg, riboflavin sodium phosphate BP 0.5mg, pyridoxine hydrochloride BP 1 mg, nicotinamide BP 10 mg, dexpanthenol BP 1 mg, benzyl alcohol BP 2% v/v, water for injection BP q.s.) (2.25 mg/Kg) were given intramuscularly at different sites for 5 days, Iron Dextran 600mg (6ml) once a week for 3 weeks, 1 ml tetanus toxoid intramuscularly and 1500 IU tetanus antitoxin subcutaneously on different injection sites with different syringes and needles. The donkey was dewormed with 370mg (14.8 ml) of Albendazole suspension *per os* (5mg/kg) and was also repeated two weeks after. 2.96 mg (3.5 ml) of Penicillin-streptomycin (Penicillin G 200 mg and dihydrostreptomycin 250 mg) 0.04 mg/Kg injection was given intramuscularly for 5 days. . Animal was also placed on balanced ration. However, it was observed after two weeks of treatment that the sizes of the exuberant granulation tissue on all sides had reduced with less bleeding (Fig 2a-c)

### 2.5. Surgical excision

**Stabilization and aseptic preparation:** Fluid (Lactated Ringer's solution (Ashmina Ltd, Nigeria) was administered via jugular venipuncture. The skin around the wound was aseptically prepared by slipping, scrubbing and sterilized with povidone iodine.

**Anaesthesia:** Donkey was pre-medicated with 0.03 mg/kg Acepromazine (Acepromazine maleate ® Vedco.INC, St Joseph, USA) via jugular venipuncture followed 30 minutes later by 1.1mg/kg xylazine (xylazine®, 2% inj., Dutch farm International B.V. Netherlands) Following apparent sedation (head lowered with relaxed body), Anaesthesia was induced with 2.8mg/kg IV ketamine (ketanir, 5% Aculife health care ltd. Sachana, India) and 0.1/ kg IV diazepam (Valium Swipha pharma ltd, Lagos). Maintenance was with one third induction dose of both ketamine and xylazine.

**Patient positioning and draping:** The Donkey was placed on lateral recumbency and the limb draped for surgery.

**Granulation tissue excision:** Surgical excision was achieved with electrosurgical machine (Electrosurgery Force 1, Pfizer valleylab, USA) with a monopolar hand piece (Fig 4). Excised tissue was submitted for histopathological examination.

## 2.6. Histological Examination

Excisional biopsies from the wound were fixed in 10% neutral buffered formalin for histological processing, stained with Haematoxylin and counterstained with Eosin for microscopic examination. Histologically, there was abundant granulation tissue characterized by marked neovascularization (formation of new capillaries), neutrophilic exocytosis in the midst of necrotic cellular debris on the epithelial surface. There was also marked proliferation of fibroblasts arranged perpendicular to the newly formed capillaries in dermis, diffuse infiltration of inflammatory cells including macrophages and lymphocytes while neutrophils accumulated on the wound surface/margin. There was haphazard collagen deposition and obliteration of adnexa (Fig 3a-d)

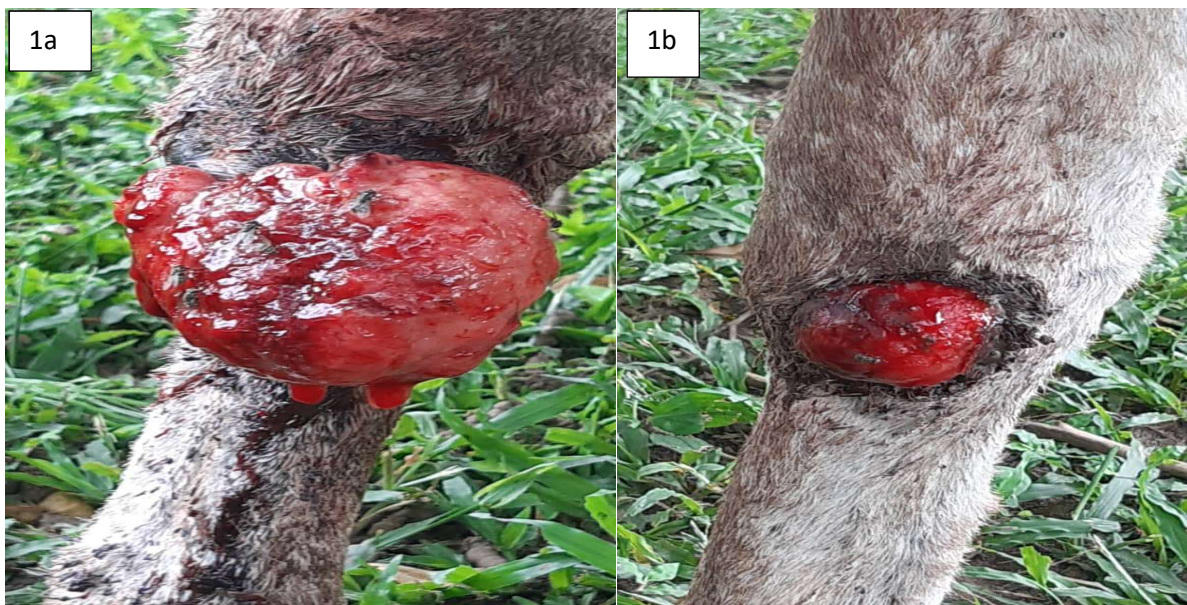

Fig 1(a-b): bilateral swollen masses around the knee joints.

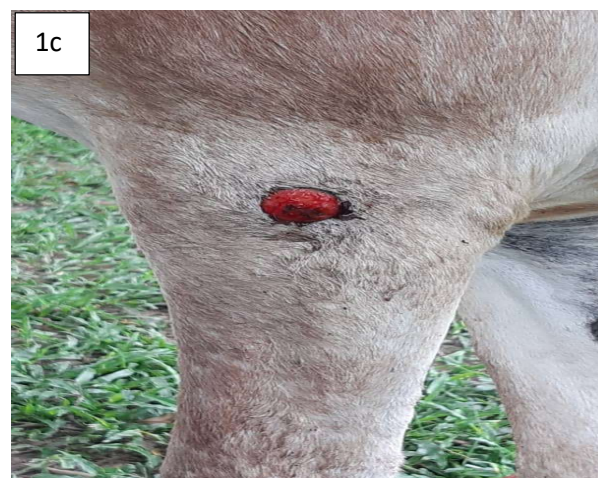

Fig 1c: swollen mass around the left elbow joint.

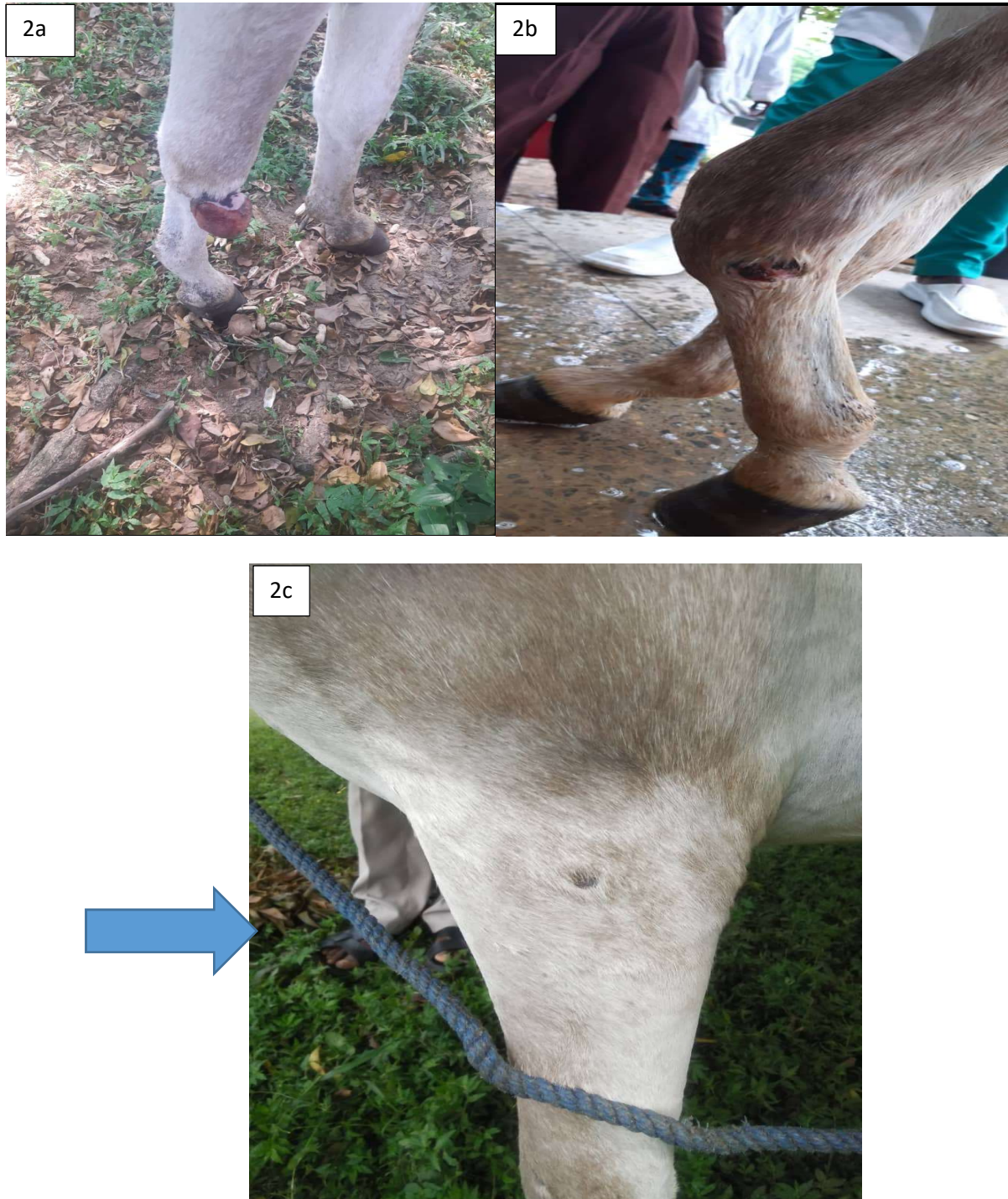

Fig 2(a-c): Picture showing reduction in sizes (atrophy) of all tissues.

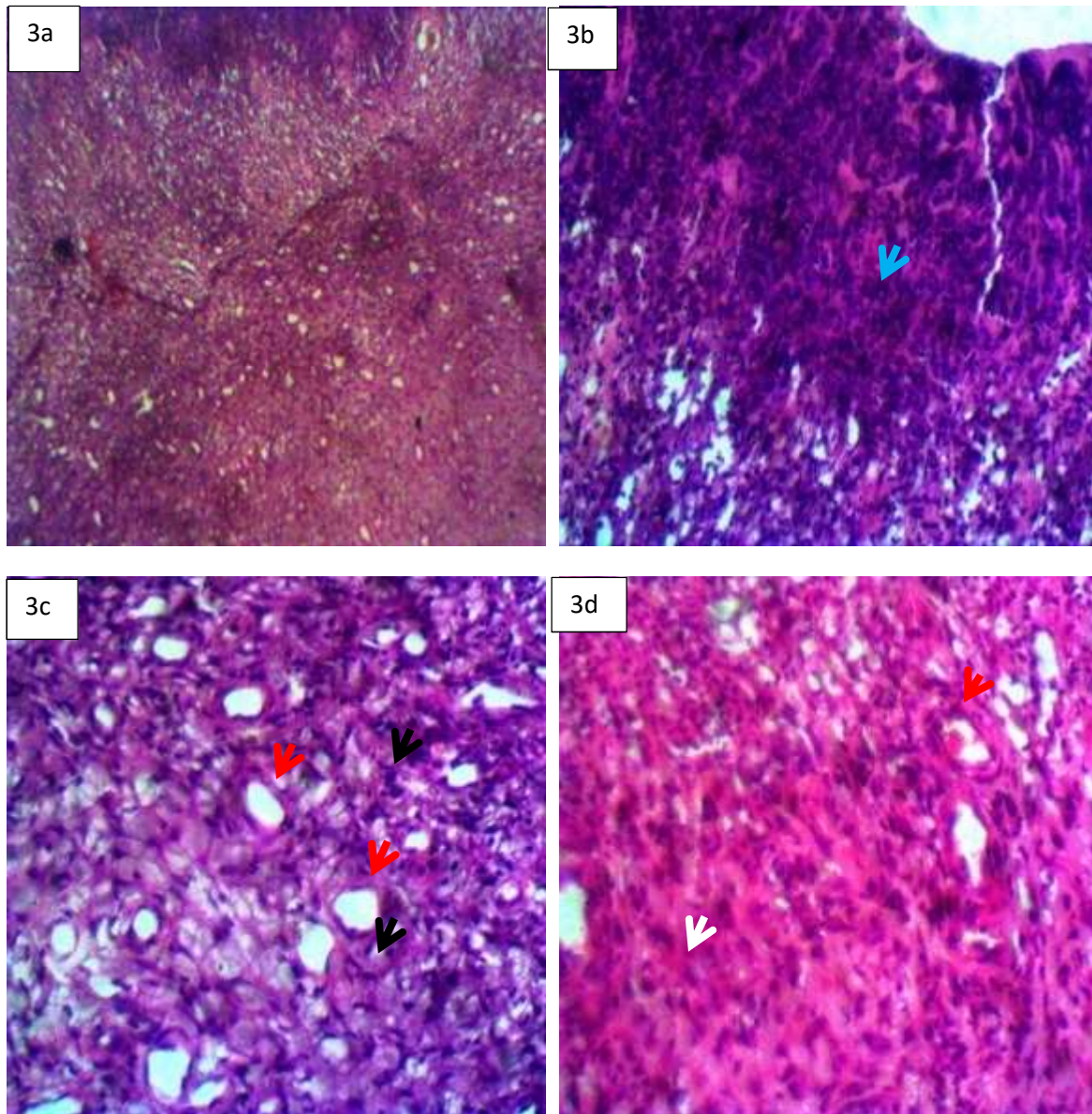


Figure 3. a) Histological section of wound biopsy showing granulation tissue. HE x100. b) Neutrophilic exocytosis (blue arrow) in the midst of necrotic cellular debris on the epithelial surface. c) Formation of new capillaries (red arrows) and proliferation of fibroblasts (black arrows) in dermis. d) Collagen deposition (white arrow) and obliteration of adnexa. HE x400

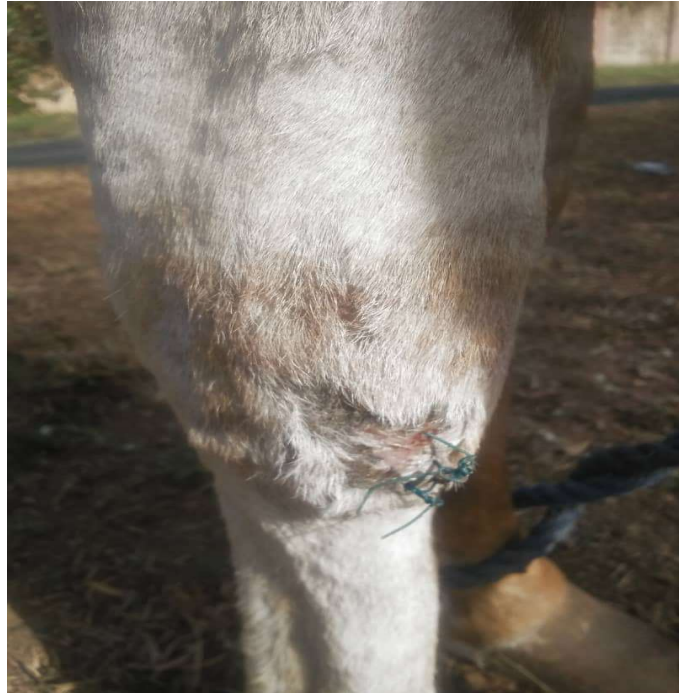

Figure 4: Site of wound after surgical excision.

### 3. DISCUSSION

Wounds involving the distal aspect of the limbs are most prevalent in equine species and frequently associated with trauma (Kayode, 2017). The wound of the donkey in this case resulted from a kick from a ram during a fight. Healing in this case was delayed as often the case with wounds of equine as compared with other species (Ali and Radad 2011; Fiorella *et al.*, 2014). The donkey was in pain at presentation. Donkeys with lower extremity wounds usually exercise intolerance due to persistent pain and varying degrees of lameness excited by the wounds. Management could be very challenging and healing delayed due to the sparse skin and muscle tissues that inhibit wound contraction (Wilmink and van Weeren 2005). The proximity of the wound to movable joints and to the ground as in this case predispose such to contamination, infection and chronicity (Theoret and Wilmink 2013).

The concurrent infections of the donkey with *Trypanosoma congolense* with their attendant immunosuppression and hemolysis might have resulted in the observed macrocytic hypochromic anaemia and contributed immensely to the delayed wound healing (Addisu *et al.*, 2017). The resultant chronic inflammation causes the release of tissue-damaging lysosomal enzymes and Transforming Growth Factor beta (TGF $\beta$ ) which overstimulate fibroplasia, leading to the formation of exuberant granulation tissue (Van Den Boom 2002). The neuro-puritis associated with *Oxyuris* infection results in discomfort that may cause the donkey to embark on frequent sand-bath thus further contaminating the wound (Mohamad *et al.*, 2019). An improvement in wound healing and atrophy of the granulation tissue were observed following management of *trypanosome* and *Oxyuris* infection and improved nutrition.

Granulation tissue is formed faster in equids (Van Den Boom 2002), probably due to poor vascularization of the tendons and scarce skin at the extremities. This new and abundant tissue seems to push the wound edges apart as in this case (Fig 1a-c). It was apparent microscopically that fibroblasts continued to proliferate in the wounds even after granulation tissue has filled the wound bed (Fig 3c). Several agents have been used to treat or prevent the development of exuberant granulation tissue, but excision of the protruding tissue has been recommended as the best treatment option (Wilmink and Van Weeren 2004). In this case, the exuberant tissues was excised with electrosurgical machine (Electrosurgery Force 1, Pfizer valleylab, USA) with a monopolar hand piece. After the above medical treatment and good plane of nutrition which probably improved the immune status of the donkey the exuberant granulation tissue atrophied and the PCV steadily rose to 40 percent. Thus, there was indication of delayed wound healing stemming from influence of concurrent infections.

#### **4. CONCLUSION**

This paper has further stressed the effects of parasitic infections (*T. congolense* and *Oxyuris equi*) on wound healing and the need for diagnosis and application of right treatment options to enhance wound healing especially in the equine species.



## REFERENCES

1. Addisu Awukew, Getachew Terefe, Tilaye Demisie, Eyob Eshetu. 2017. Immune Responses to Animal Trypanosomosis: A Review. *Journal of Scientific and Innovative Research*; 6(4): 142-150.
2. Ali M. and Radad K. 2011. Cod liver oil/honey mixture: An effective treatment of equine complicated lower leg wounds. *Veterinary World*, Vol.4 (7): 304-310.
3. Benoit Stijlemans, Patrick De Baetselier, Stefan Magez, Jo A. Van Ginderachter, Carl De Trez 2018. African Trypanosomiasis-Associated Anemia: The Contribution of the Interplay between Parasites and the Mononuclear Phagocyte System. *Front Immunol*; 9: 218.
4. Blench R. 2004. The history and spread of donkeys in Africa. In: Starkey P, Fielding D (eds) *Donkeys, People and Development. A Resource Book of the Animal Traction Network for Eastern and Southern Africa (ATNESA)*. ACP-EU Technical Centre for Agricultural and Rural Cooperation (CTA), Wageningen, p 244.
5. Fiorella Carnevali, Marco Argentieri, Graziano Ippedico, Carlo Alberto Minniti, Luigi Amodio, Luigi Mellano, Stephen Andrew van der Esch 2014. Managing Horse Wounds either presenting or not with Exuberant Granulation Tissue Using an Innovative Wound Dressing: A Retrospective Non-Controlled Study. *Journal of Animal and Veterinary Sciences*. Vol. 1, No. 2, pp. 6-16.
6. Kayode O.A. 2017. Epidemiological study on wound distribution pattern in horses presented at two veterinary clinics in south west, Nigeria between 2007- 2010. *J Dairy Vet Anim Res*.5(4):127–129.
7. Mohamad Tolouei, Seyed Abdolhamid Hosseini, Saeid Mostofi. 2019. Occurrence of progressive and corrosive lesions in perineal area of a Kurd stallion due to oxyuris equi. *Veterinary Journal of Equine Sciences* 2019(1) 27-32.
8. Naessens J. 2006. Bovine trypanotolerance: a natural ability to prevent severe anaemia and haemophagocytic syndrome? *Int J Parasitol* 36:521–8.
9. Nejash Abdela, Endale Teshome, Abdi Hassan and Feyissa Begna Deressa. 2017. Prevalence and associated risk factors of equine wound in and around Asella town, South Eastern Ethiopia. *Journal of Veterinary Medicine and Animal Health*. Vol. 9(4), pp. 63-71.
10. Paganella J.C., Ribas L.M., Santos C.A., Feijó L.S., Nogueira C.E.W. & Fernandes C.G. 2009. Abordagem clínica de feridas cutâneas em equinos. *Revista Portuguesa de Ciências Veterinárias*. 104: 13-18.
11. Starkey P, Starkey M. 2004. Regional and world trends in donkey populations. In: Starkey P, Fielding D (Eds). *Donkeys, people and development. A resource book of the Animal Traction Network for Eastern and Southern Africa (ATNESA)*
12. Theoret C.L. & Wilmink J.M. 2013. Aberrant wound healing in the horse: naturally occurring conditions reminiscent of those observed in man. *Wound Repair Regen*, 21 (3), 365-371.
13. Theoret C.L. & Wilmink J.M. 2017. *Equine Wound Management, Third Edition*, Published by John Wiley & Sons, Inc.
14. Varasano Vincenzo, Giuseppe Marruchella and Lucio Petrizzi. 2018. Exuberant granulation tissue in a horse: successful treatment by the intralesional injection of 4% formaldehyde solution. *Veterinari Italiana*, 54 (2), 155-159.
15. Wilmink J.M. and Van Weeren P.R. 2004. Treatment of Exuberant Granulation Tissue. *Clin Tech Equine Pract* 3:141-147.

16. Wilmink JM, and van Weeren PR 2005. Second-Intention Repair in the Horse and Pony and Management of Exuberant Granulation Tissue. *Vet Clin Equine* 21:15–32
17. Van Den Boom R, Wilmink JM, O’Kane S, et al., 2002. Transforming growth factor-b levels during second intention healing are related to the different course of wound contraction in horses and ponies. *Wound Rep Regen* 10:188–94.
18. William Del Conte Martins, Denis Steiner , Arthur Borges Neto , Salviano Tramontin Belettini Carla Faria Orlandini , André Giarola Boscarato , Igor Bueno Volpato and Luiz Romulo Alberton. 2018. Graft of Small Patch of Partial Thickness in Equine Wound. *Acta Scientiae Veterinariae*, 46(Suppl 1): 252.